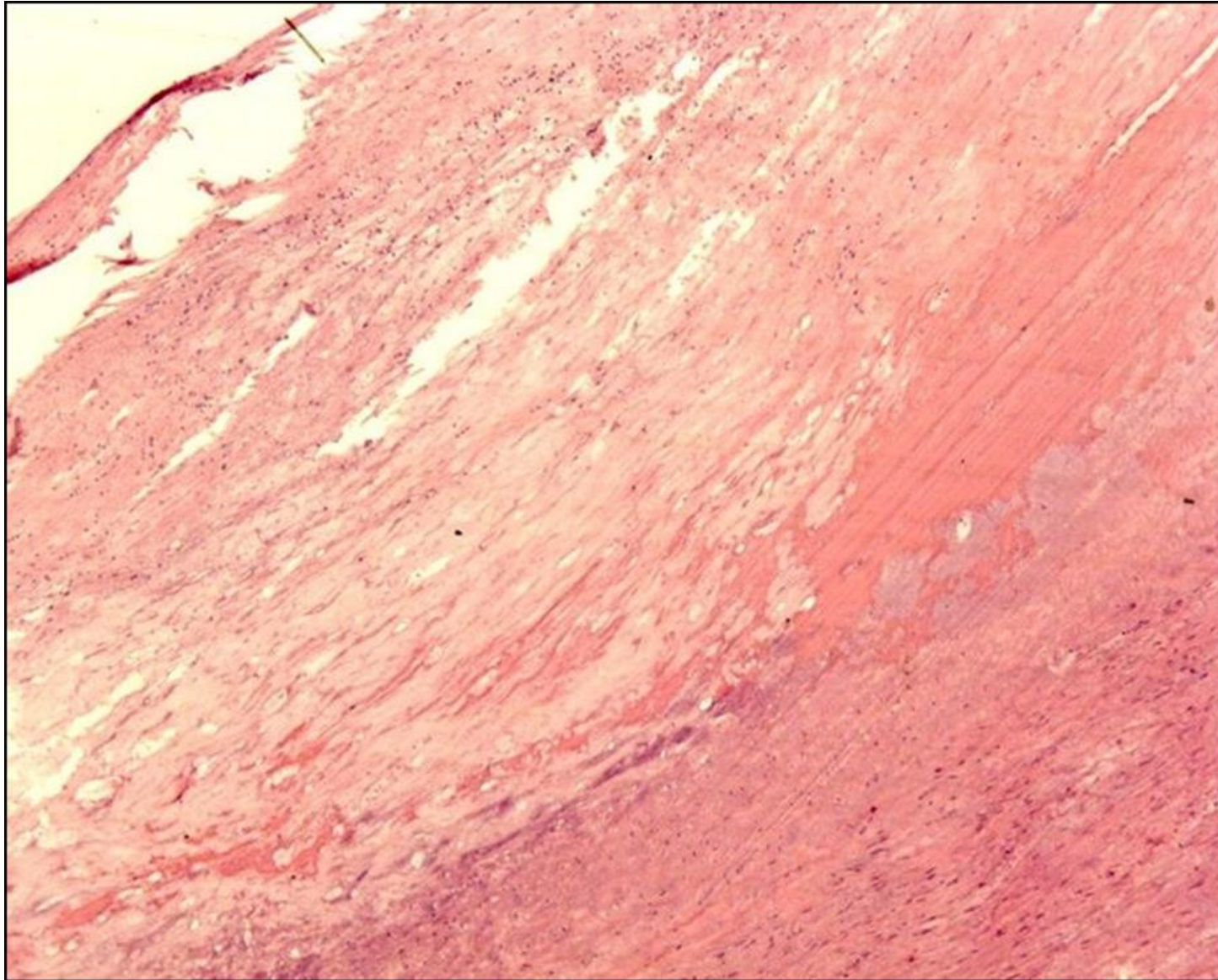
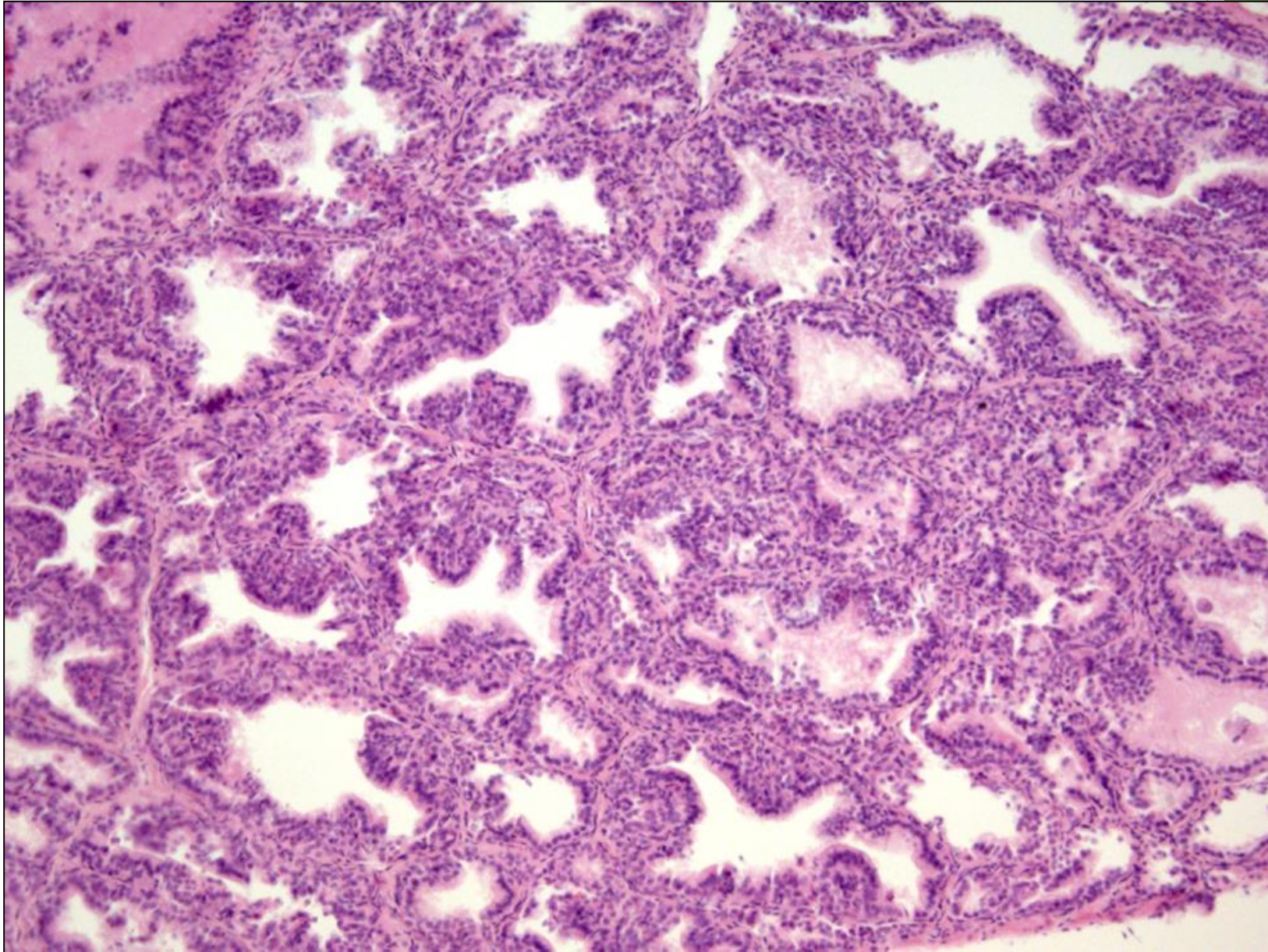


Microscopic specimens
of the boundary control
in the third section

Atherosclerotic plaque in the aorta

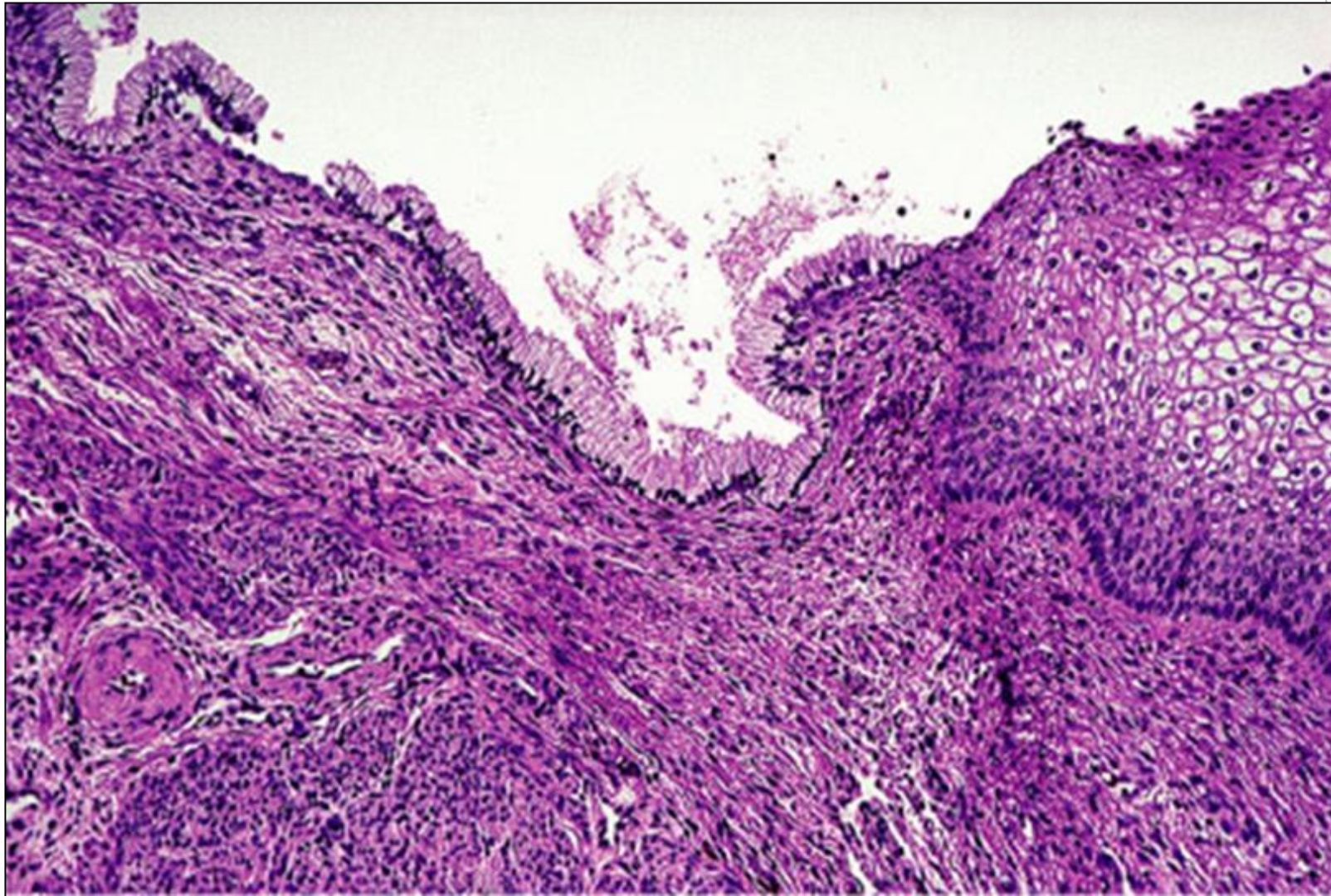


Graves' goiter

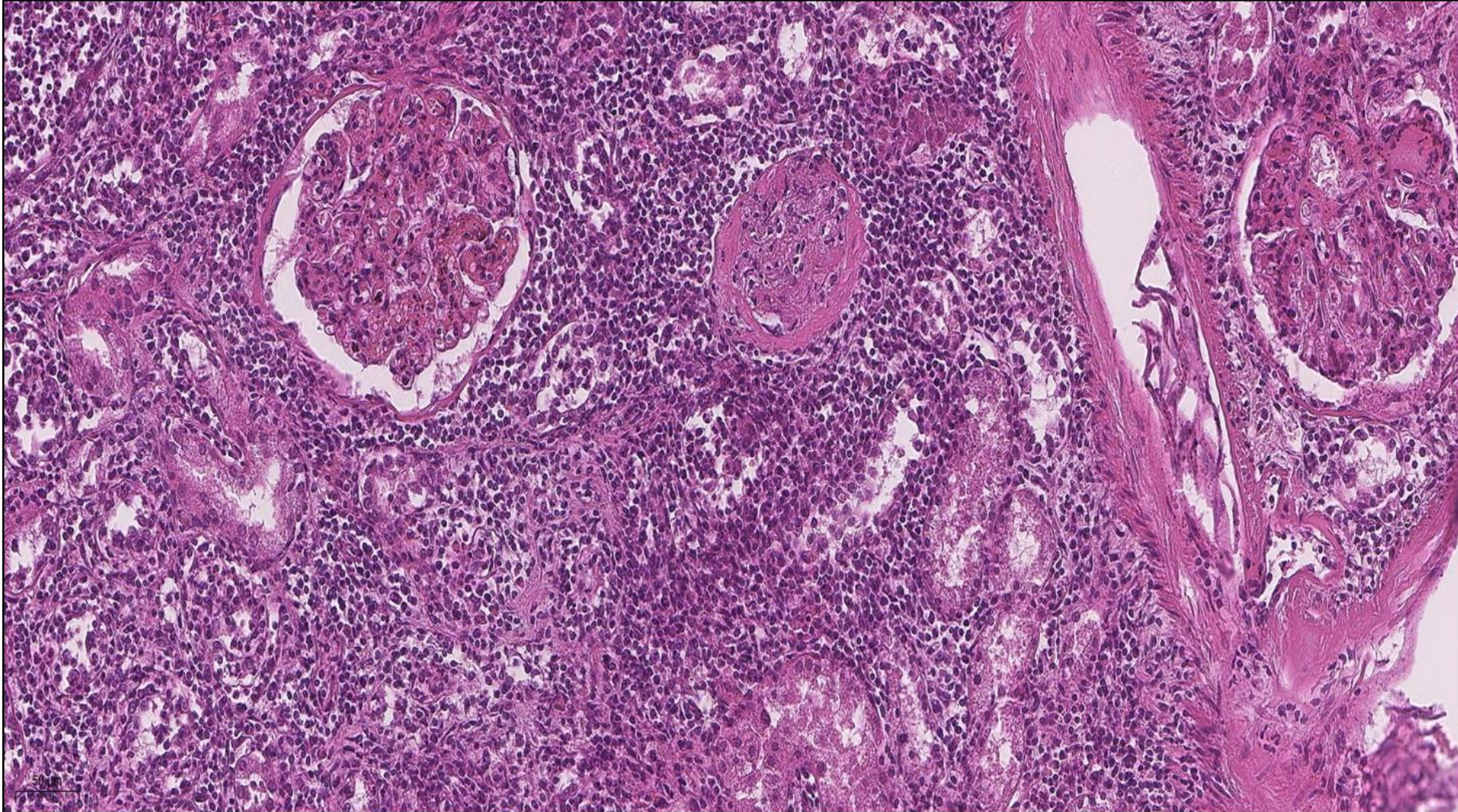


Cervical endocervicosis

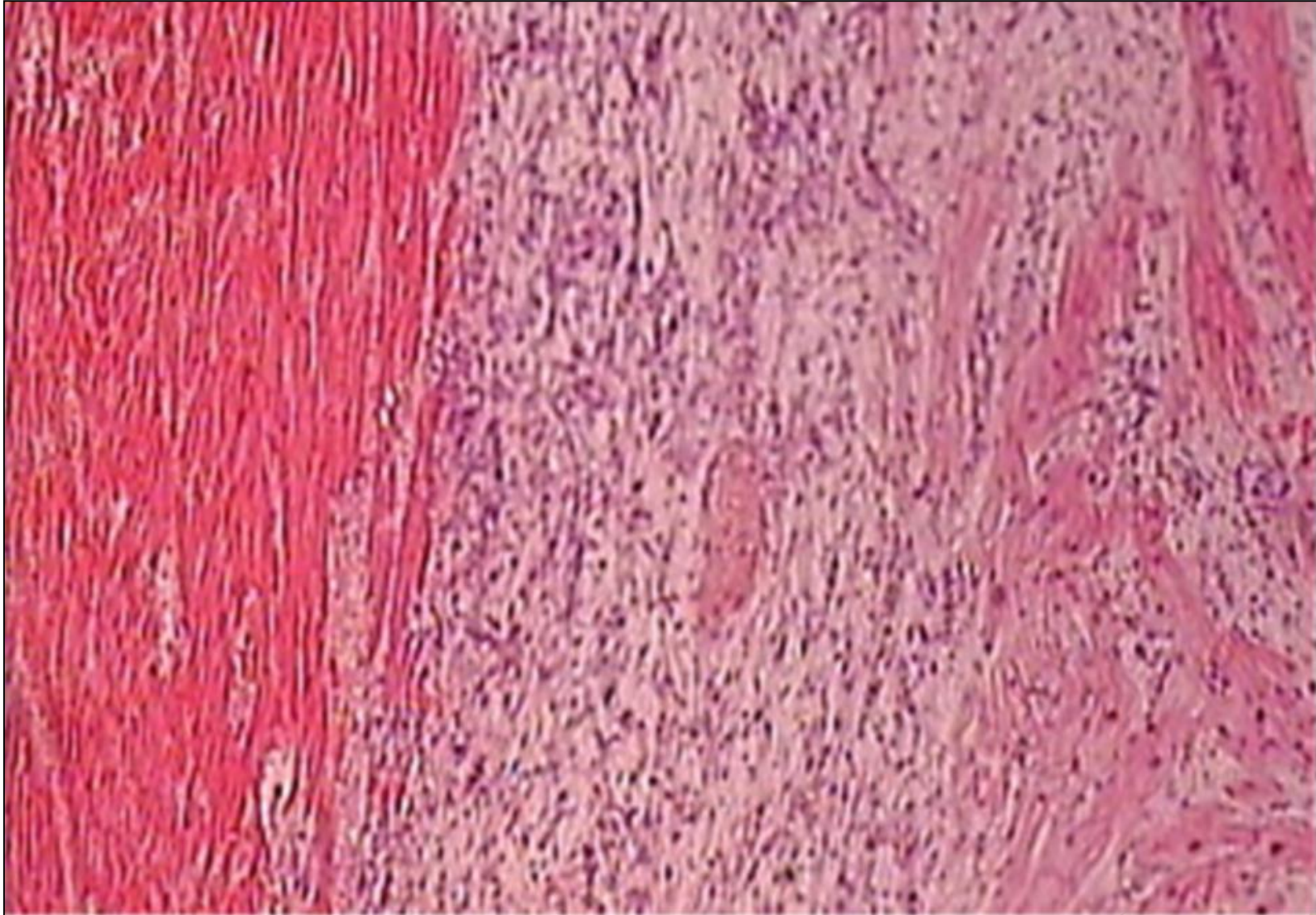
1



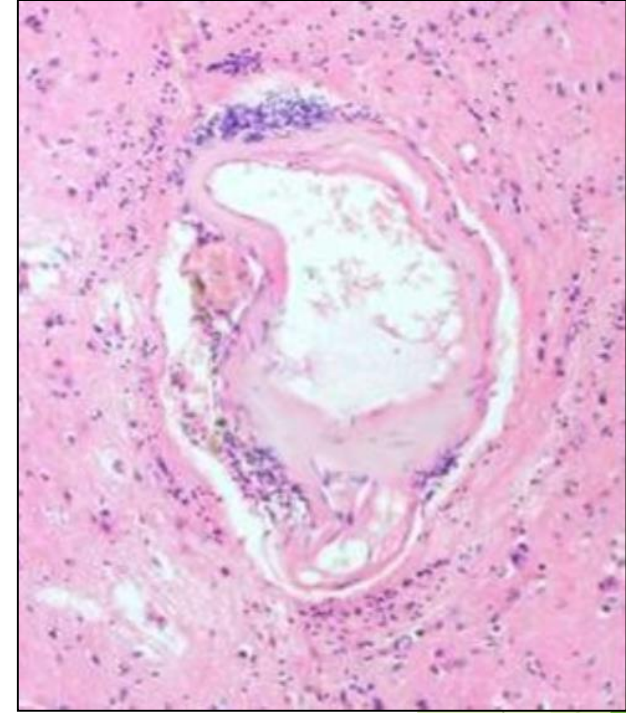
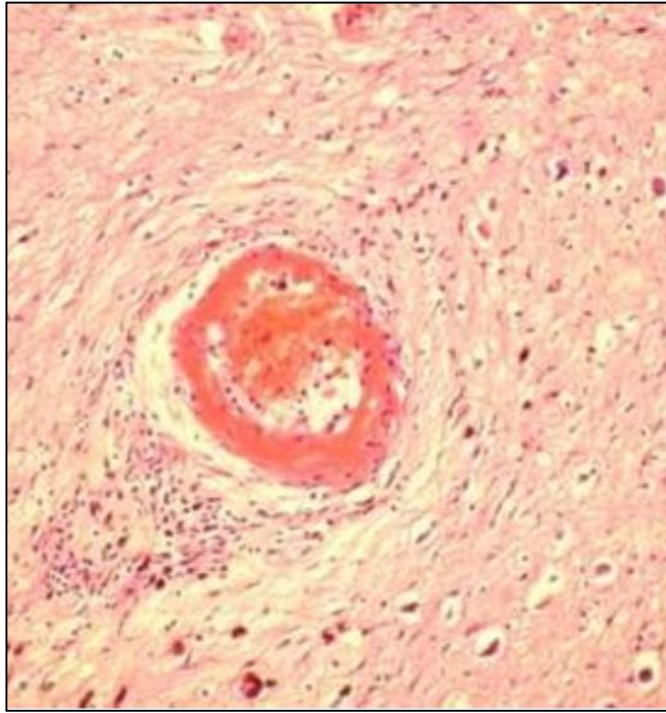
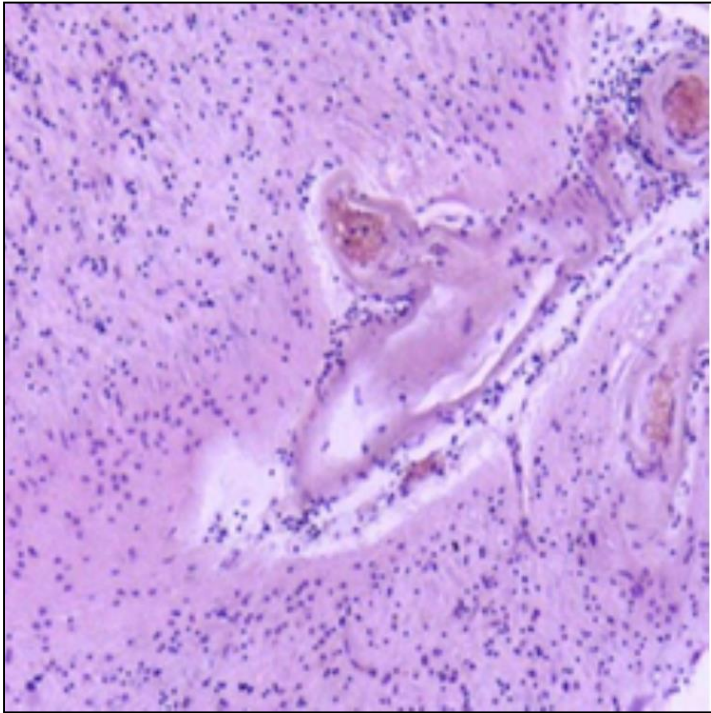
Chronic pyelonephritis



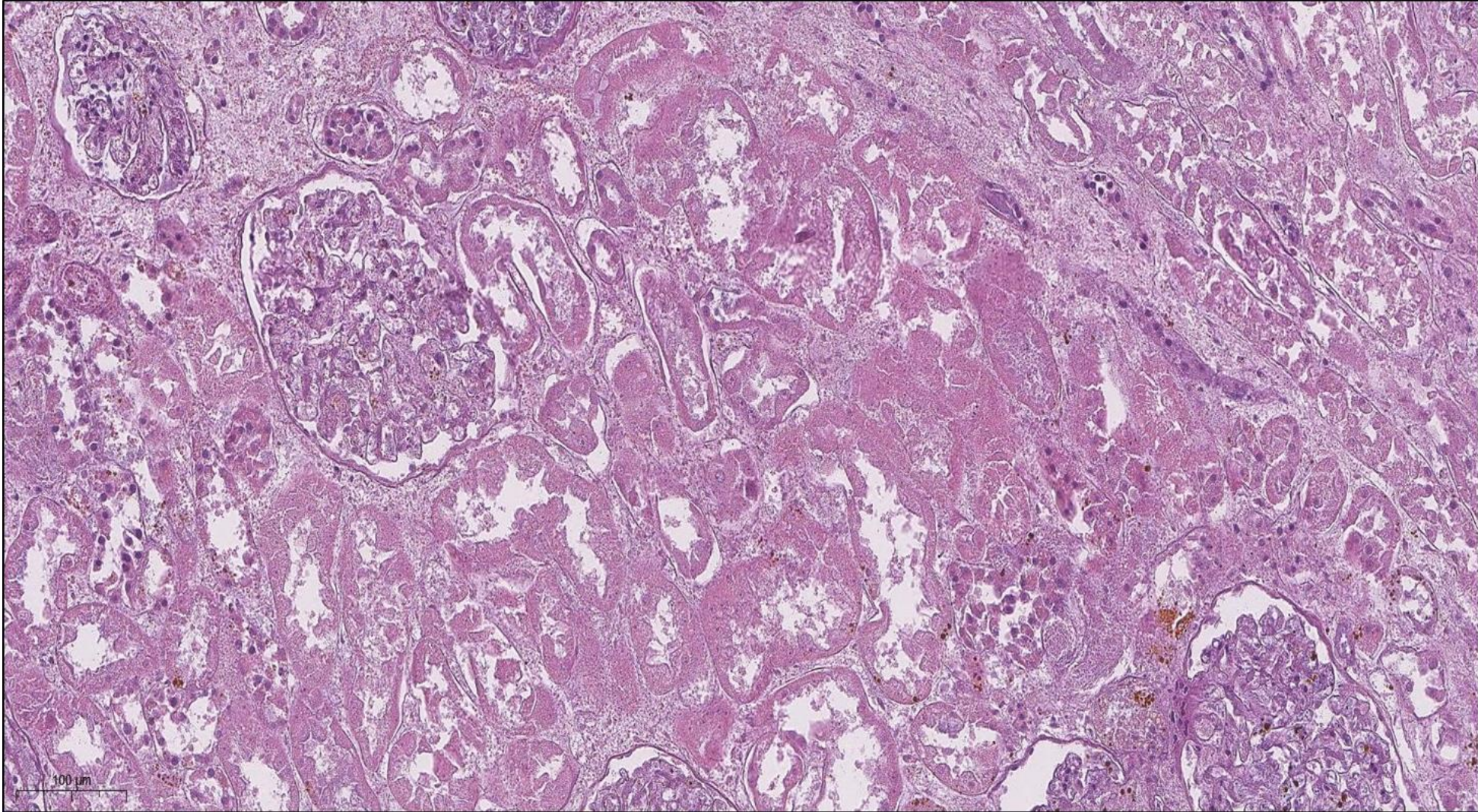
Transmural myocardial infarction with the onset of organization



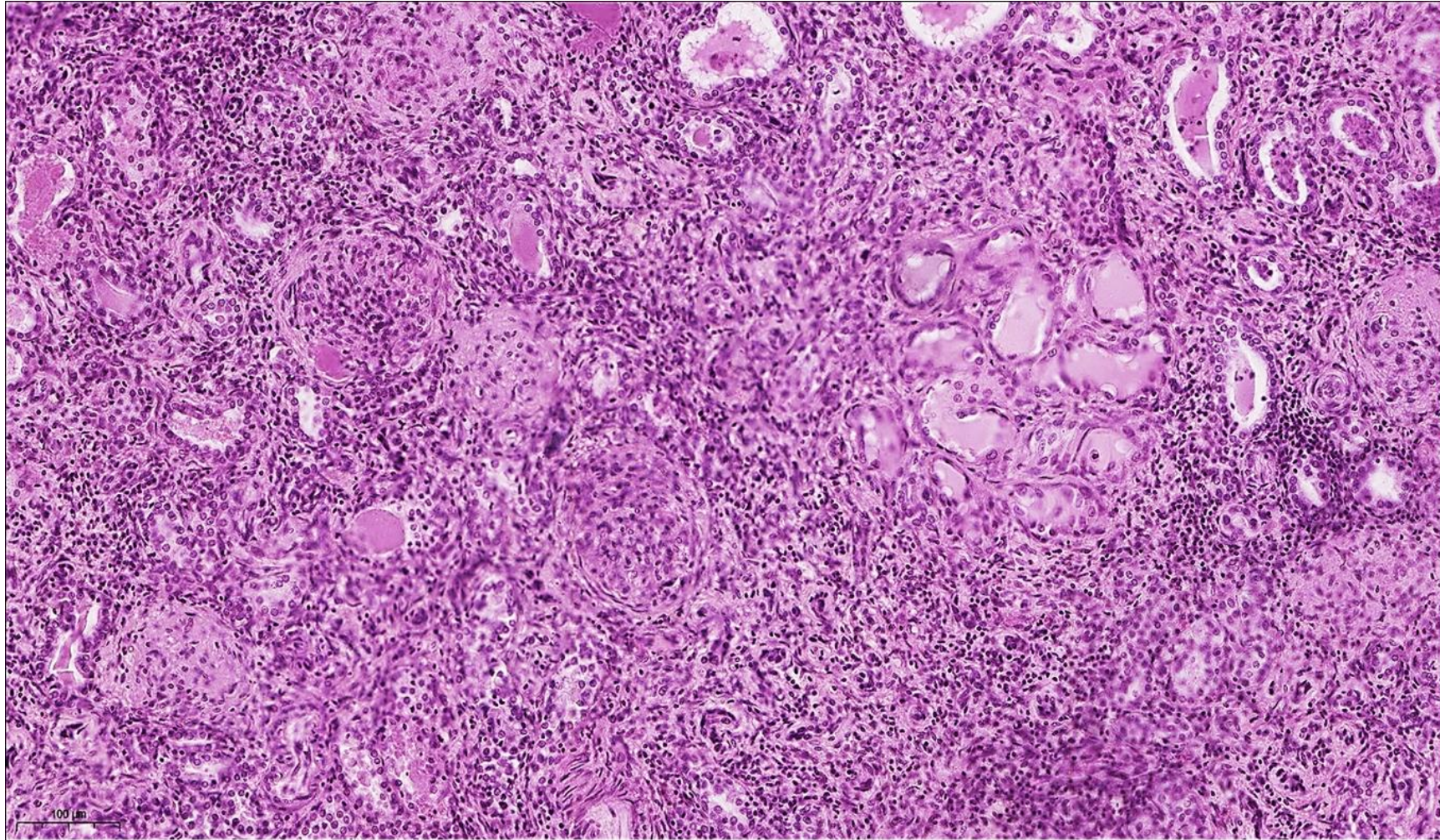
Cerebral vessels in hypertonic disease



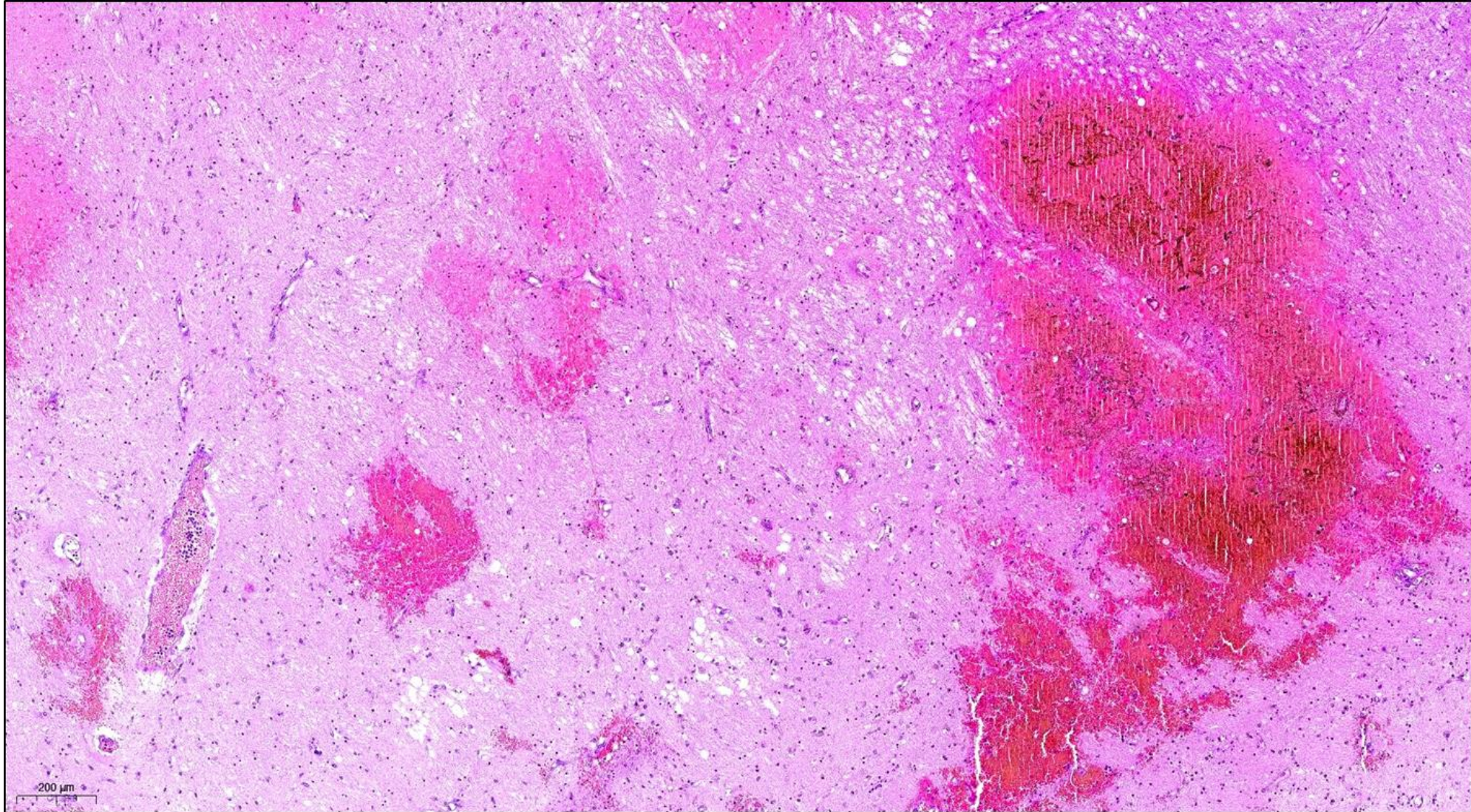
Necrotizing nephrosis



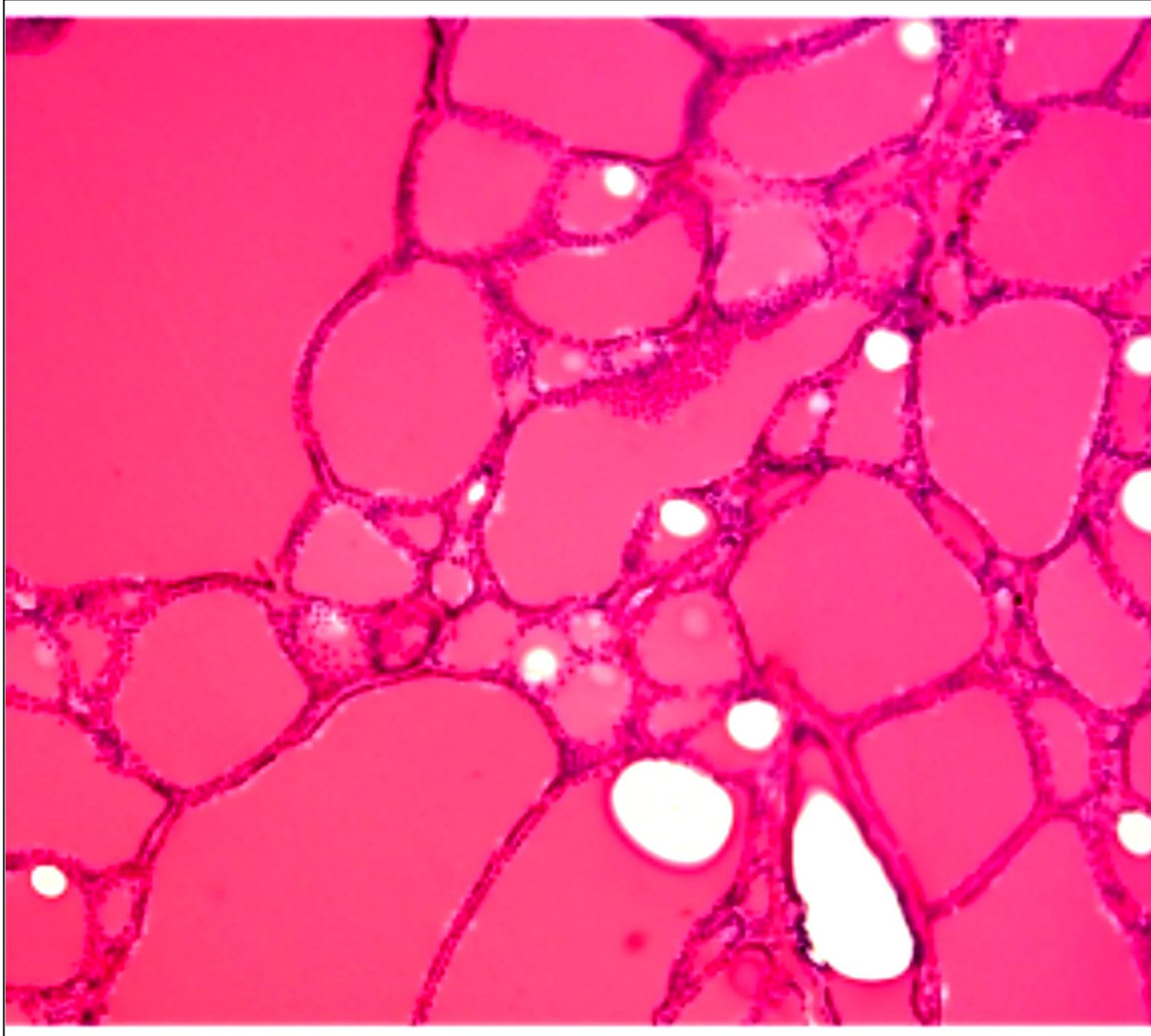
Chronic glomerulonephritis with wrinkling



Cerebral hemorrhage as hemorrhagic infiltration



Colloidal Struma (goiter)



Recurrent verrucous endocarditis of the mitral valve

